

Alessandria, 10 Maggio 2014

UNIVERSITA' DEGLI STUDI DI TORINO

Scuola di Medicina

Dipartimento di Scienze Chirurgiche, Direttore: Roberto Albera
Corso di Laurea Specialistica in Odontoiatria e Protesi Dentaria,
Direttore: Prof. Stefano Carossa



Confronto tra due Protocolli di estrazione dentaria con Plasma Ricco di Fattori di Crescita (PRGF) in pazienti trattati con Bifosfonati per via endovenosa

Dr. Ernald Duni

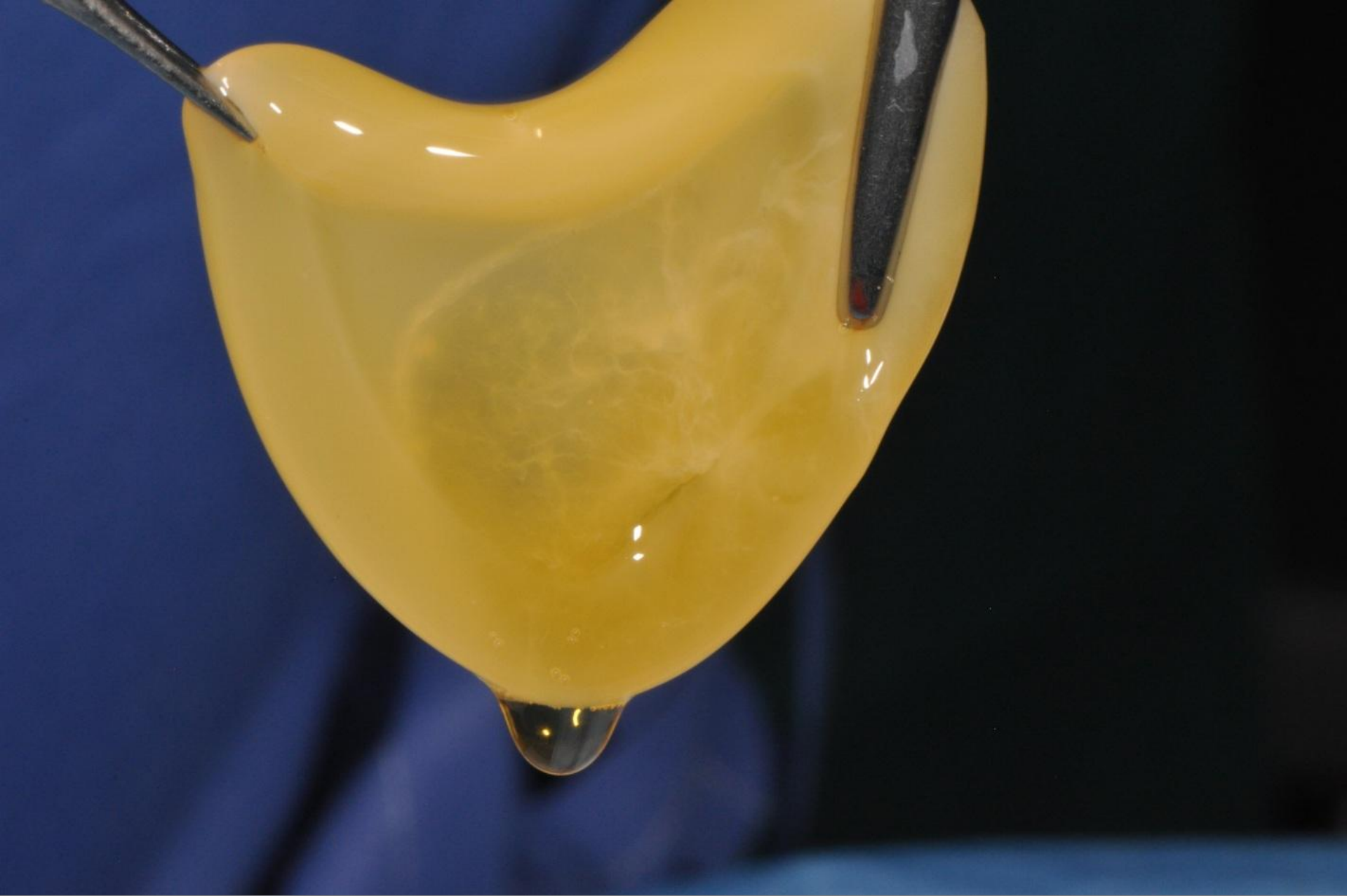


Valutazione del nuovo
protocollo di estrazione

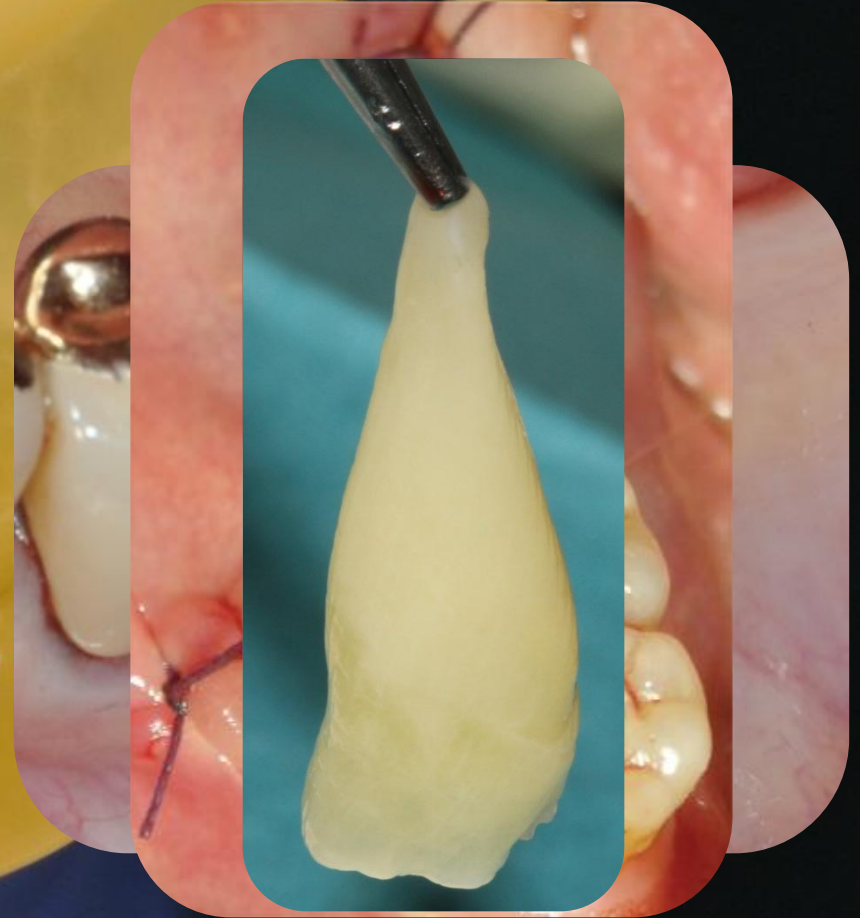
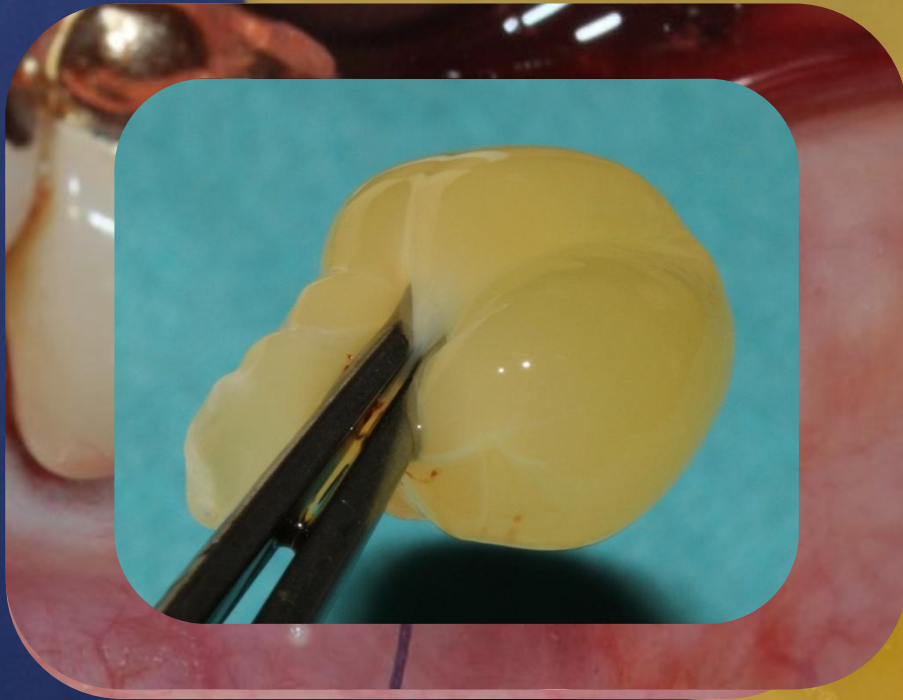

Confronto con il precedente
protocollo

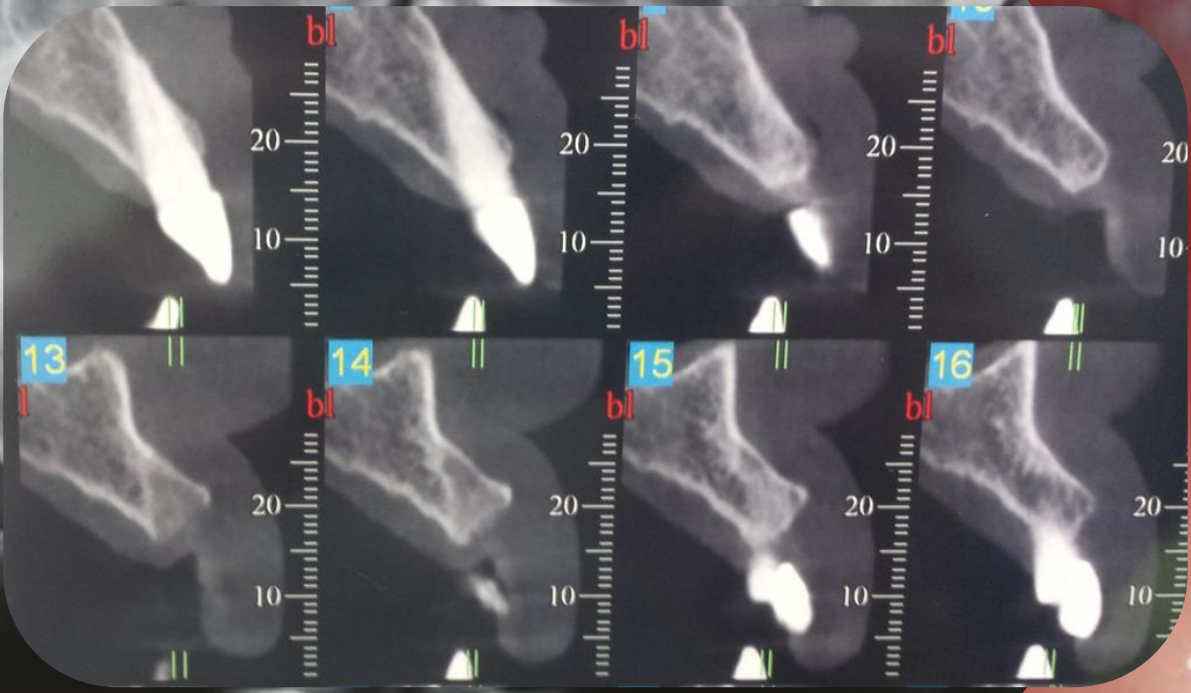
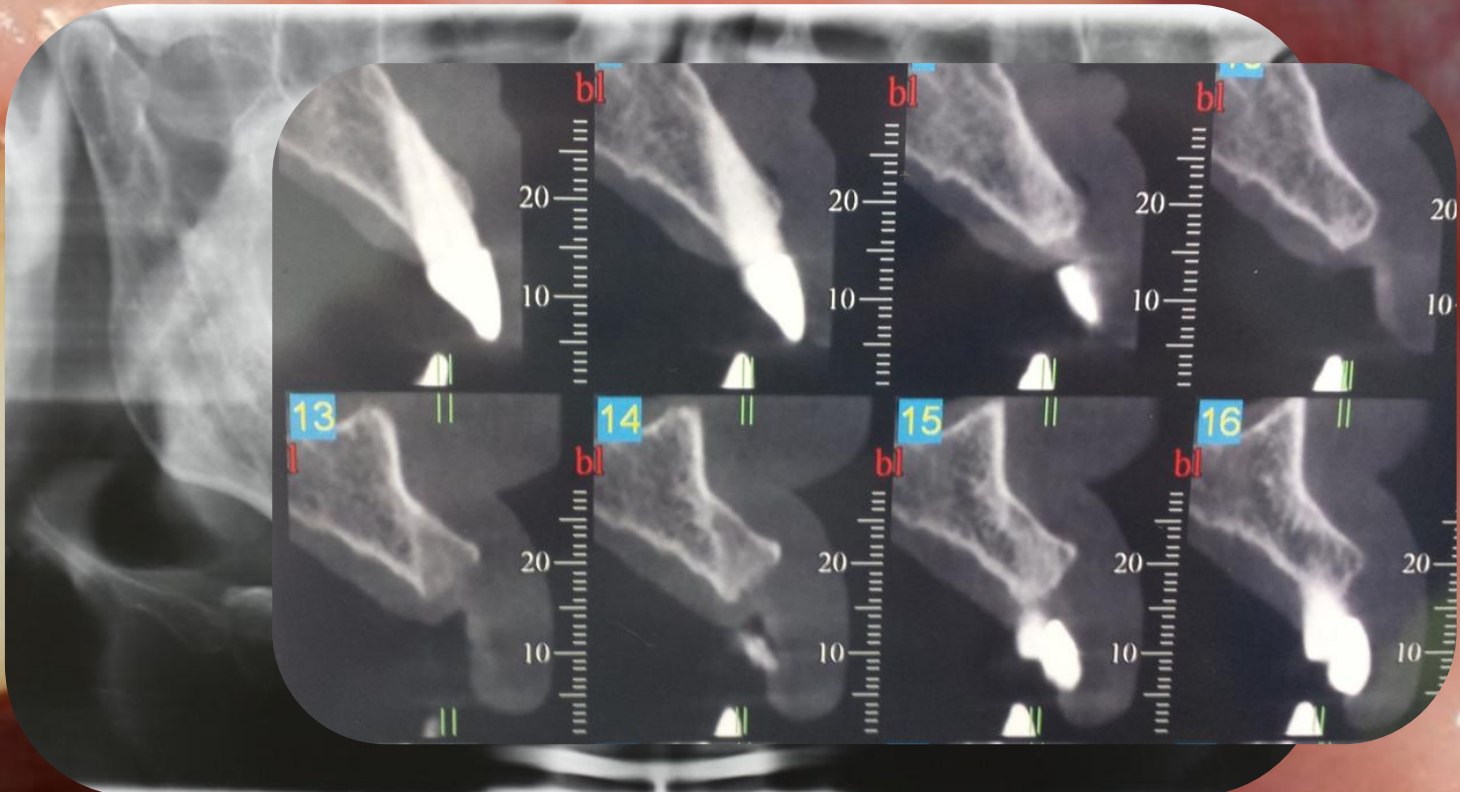
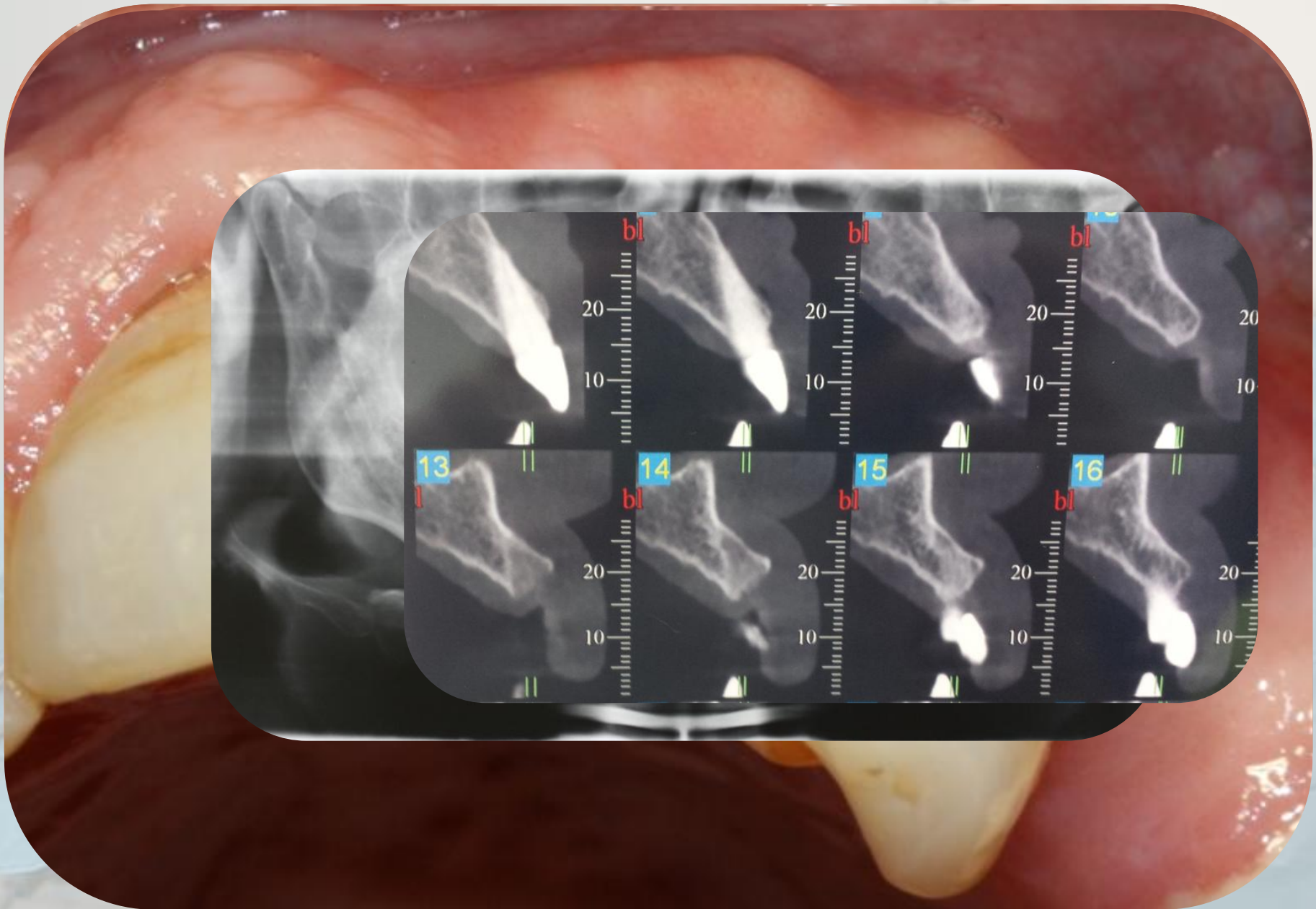




PRGF



- Anitua E, Sanchez M, Zalduendo M et al. Fibroblastic response to treatment with different preparations rich in growth factors. *Cell Prolif* 2009;42:163-70.
- Rutkowski JL, Fennell JW, Kern JC et al. Inhibition of alveolar osteitis in mandibular tooth extraction sites using platelet rich plasma. *J Oral Implantol* 2007;33:116-21.
- Mozzati M, Martinasso G, Pol R et al. The impact of plasma rich in growth factors on clinical and biological factors involved in healing processes after third molar extraction. *J Biomed Mater Res* 2010;Epub ahead of print.



97 pazienti, 360 estrazioni

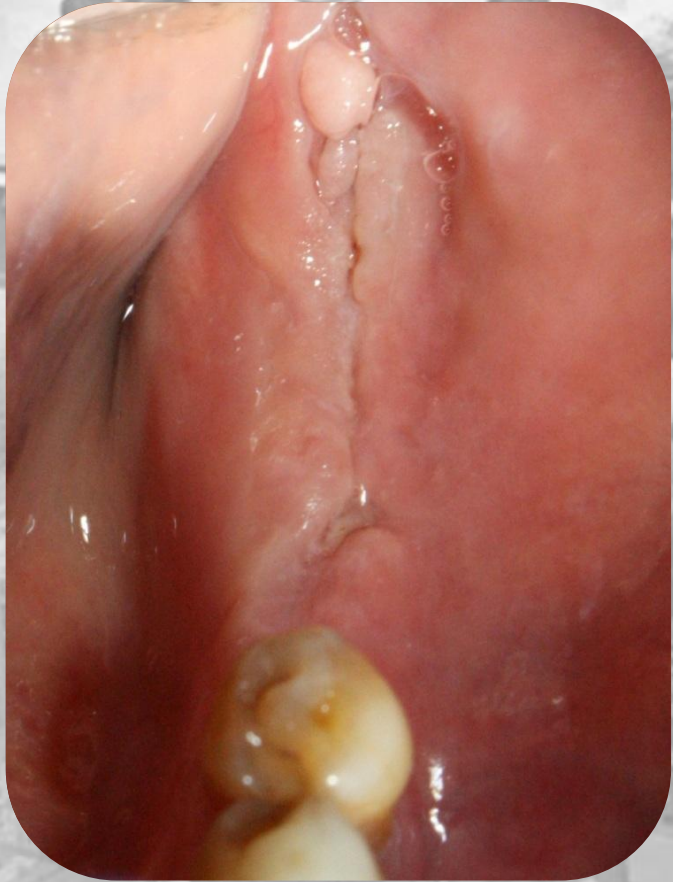
	Protocollo 1	Protocollo 2	p
N° Pazienti	64	97	
F/M	45/19	69/28	
Età Media	64.7 (+-10.3)	67.9 (+- 11.2)	0.07
N° cicli medi	15.3 (+- 16.6)	27.1 (+- 22.8)	0.0005
N° denti estratti	220	360	
Mand/masc	113/107	182/178	
Complicanze	6/220	5/360	0.64
	2.7 (0.8-5.0)%	1.4 (0.6-3.2)%	

Fattori di Rischio

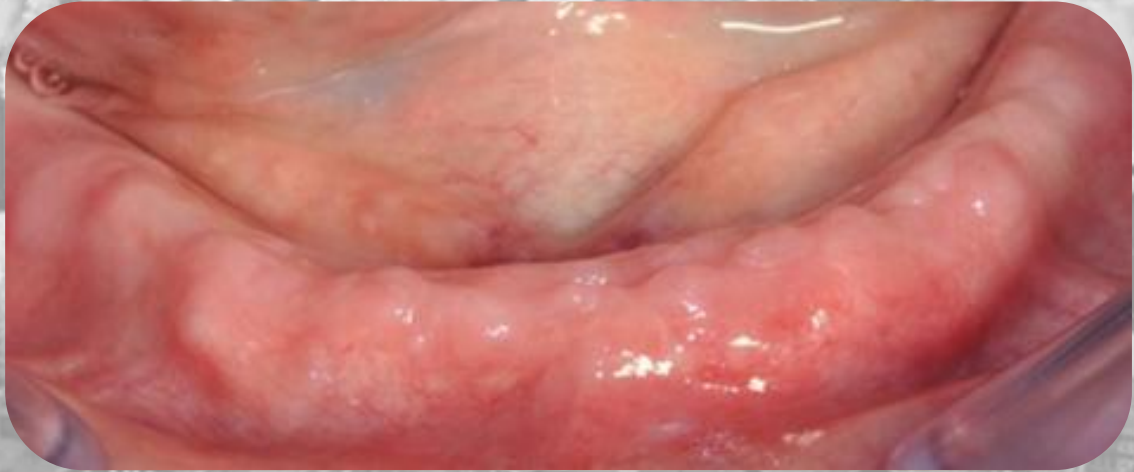
	Protocollo 1	Protocollo 2	p
N° Pazienti	64	97	
F/M	45/19	69/28	
Età Media	64.7 (+-10.3)	67.9 (+- 11.2)	0.07
N° cicli medi	15.3 (+- 16.6)	27.1 (+- 22.8)	0.0005
N° denti estratti	220	360	
Mand/masc	113/107	182/178	
Complicanze	6/220	5/360	0.64
	2.7 (0.8-5.0)%	1.4 (0.6-3.2)%	

Complicanze

Protocollo 1



Protocollo 2



TO DO LIST

-
-
-
-
-

Incidenza e gravità di complicanze ridotte

Minor tempo di esecuzione

Chirurgia meno invasiva

A grayscale image of a tunnel with a bright light at the end, creating a strong sense of perspective and depth. The tunnel walls are textured and the light at the end is very bright, almost white.

Grazie per
l'attenzione!